

UDC 616-002.951.21-089

Hydatid cyst of the rib (clinical case). Analysis of published cases

Myrzakhanov Yerik Kanatovich

"Semey" Medical University

ORCID: 0000-0002-6546-037X

Zharkimbayeva Almira

"Semey" Medical University

ORCID: 0000-0003-3487-0170

Gamzaeva Esmira

"Semey" Medical University

ORCID: 0000-0003-3094-0151

Abstract. Echinococcal disease is one of the current zoonoses discovered in the Republic of Kazakhstan. This parasitic disease caused most often Echinococcus Granulosus is a flat worm. Due to the large number of registered cases of diseases of people and animals of the Republic of Kazakhstan, as well as due to the prevalence of the occurrence of the disease in some regions, the country is considered to be endemic. [1].

Echinococcal cysts are affected by the liver and lungs, but less than 100 cases of echinococcosis edges are registered in the literature. [2, 3]. We observed a casuistic case of an isolated echinococcal defeat of the edge of the 17-year-old patient, which led us to a deeper study of this pathology. Based on our retrospective analysis, the first similar described case was registered in Germany [9]. We analyzed published cases on the PubMed and Elsevier platform, we found in the total number of 18 patients with this pathology over the past 20 years of published materials.

The diagnosis of the disease of the affected organs is relatively simple, however, cases of nonypical localization of the cyst may be complex in diagnosis, as in the case of the echinococcosis of the rib. Methods of diagnostic visualization can differentiate pathology, but in rare cases the diagnosis remains uncertain to operation, as in our case.

Keywords: *Echinococcosis of the rib; Cyst ribs; Echinococcosis; Cestodoz bones; Echinococcus cyst; Isolated defeat of the ribs;*

Introduction

According to clinicians in recent years, a significant number of echinococcosis cases has been marked in the Republic of Kazakhstan with a tendency to increase. In the southern region of the Republic of Kazakhstan, Echinococcosis is one of the most common zoonotic diseases[4]. According to statistics, in 2016, 806 cases of echinococcosis disease were registered in Kazakhstan, in 2017 - 788, 2018- 742, 2019 - 681 cases, with the result that Kazakhstan took 3rd place in the Eurasian Union with the Middle An indicator of 0.48 per 100000 registered cases[1, 5].

There is a tendency to spread echinococcosis not only among people engaged in animal husbandry, but also among the urban population, which is due to a large extent with the insufficiently high awareness of the population, especially rural, about the ways of transmitting this disease, neglect of the disease prevention, incomplete coverage of the contingent of people with preventive medical inspections. The asymptomatic flow of the disease determines the increase in cases of heavy and complicated forms of damage to echinococcosis [4].

Among the complications of echinococcosis is the most severe and dangerous is the suppuration of echinococcal cyst, which is 17-26% and, as a rule, is accompanied by a severe violation of the functions of vital organs. Also in 1-4% of cases there is a primary defeat by echinococcosis of the human musculoskeletal system [2, 3]. Many important aspects: mechanisms of occurrence, ways of damage to organs and diagnostic methods have so far remain controversial and not fully studied, which requires a deeper and comprehensive study.

Materials and research methods

Based on the retrospective analysis carried out by us, 18 cases with echinococcal defeat of the ribs were found. Descriptions found in the Medline database were retrospective analysis. PubMed Platform, Scopus Electronic Base from Elsevier Corporation, and Scholar.Google.com is used to search for data.

Clinical case

A seventeen-year-old college student was hospitalized in a planned manner in the department of children's surgery of the university hospital of the city of families, with complaints of a long-lasting wound of the chest right, periodic pain separated from the wound. In the history: In 2016, a stupid injury was noted by a spike of a representative of a cattle in the region VIII edge, after which the fracture of the VIII rib was noted on the right, hematoma of soft tissues followed by suppuration. For a long time was treated outpatient. Due to the duration of the disease, with a periodic recurrence of the suppuration, the diagnosis of the ribs on the right to form a fistula in the regression stage was put up. Next was surveyed outpatient. It was planned to be carried out under the supervision of the front segment of the VIII edge, followed by the drainage of soft tissues.

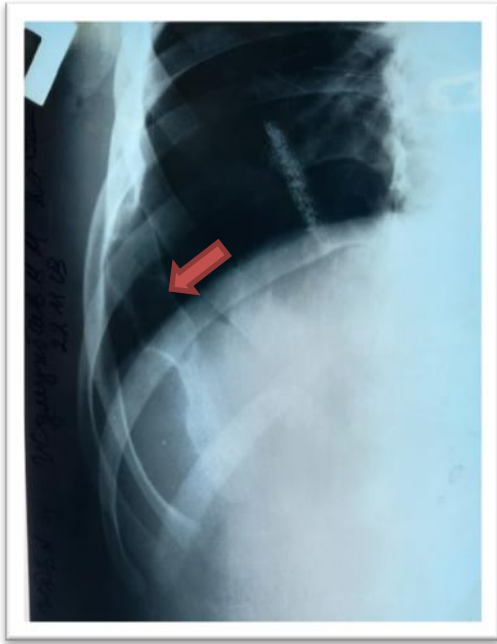

Fig.1. A targeted radiograph of the chest. On the radiograph of the right half of the chest, the deformation of the front segment VIII edges is determined, the cystoid enlightenment with dimensions of 2.0x1.0 cm and 3.0x1.5 cm (indicated by the arrow).

According to clinical, laboratory and instrumental data, the inclusion of pulmonary, pleural or closer lying muscular-intestinal structures was not observed in the process. After the preoperative preparation of the patient, in the position on the left side, a cut in the projection of VIII ribs with a length of about 5.0 cm. Macroscopic: VIII periosteum ribs thinned, the structure of the bone fragile, the presence of cavities. When attempting resection of the rib, in the field of cystic expansion, along the inner wall of VIII edges, echinococcal brushes with chitinic shells and with child cysts were found. Numerous daughter cysts were removed. The cavity is repeatedly processed by glycerol, hypertensive solution and formalin 1% in the amount of 200 ml. Produced under the supervisory resection of the front cut VIII rib.

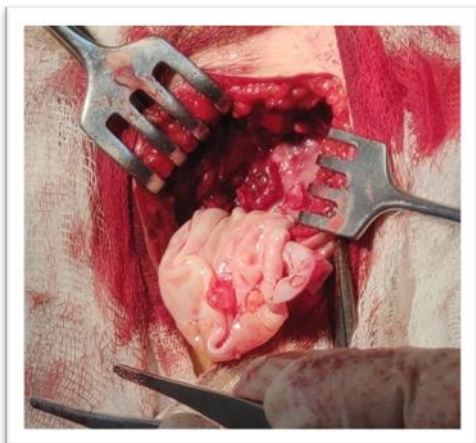


Fig 2. Intraoperative snapshot. Chitinova shell with daughter cysts.

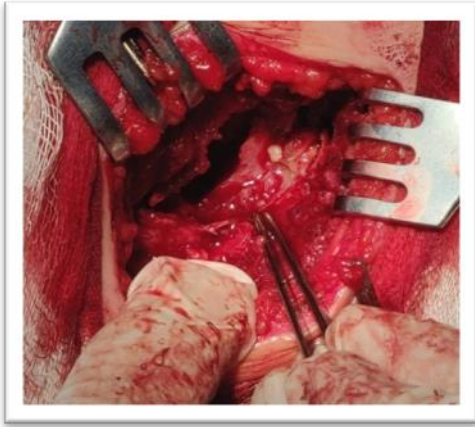


Fig 3. Intraoperative snapshot. Numerous daughter cysts in the cavity of the thinned rib.

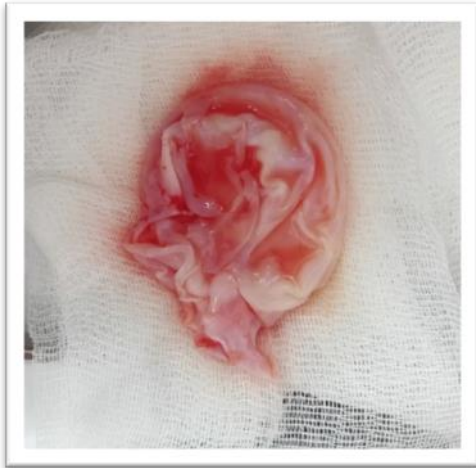

Fig 4. Macroscopic. Chitinova shell.

To verify the diagnosis, a histological study of the macro production was carried out, the conclusion-echinococcosis of the rib with suppuration. The postoperative period was carried out antiparasitic chemotherapy with Albezol 400 mg for 2 tablets per day, a course of three months with a break of 14 days between cycles; Antibiotic therapy, antihistamines, painkillers. The postoperative period proceeded smoothly, without complications. The soreness in the field of postoperative wound decreased significantly on the second day. If the patient is discharged from the hospital for 7 days, the test surveys of the abdominal ultrasound, chest radiography, craniography, showed the absence of any cystic formations. One month after the postoperative wound statement without features. Currently, the patient is under the supervision of a family physician at the place of residence.

Results

Analysis of published clinical cases on this pathology revealed the following patterns and indicators:

- The average age of patients was from 17 to 47 years. The prevalence of gender type was not observed. The general condition of all patients was described as satisfactory.
- In 12 cases, the echinococcal defeat of the ribs was described as a primary disease.
- The clinical picture was characterized in 11 cases, a sense of discomfort in the localization of the process. In 7 cases, local changes in the form of edema were observed. In the radiography of the chest, there was a descriptive picture of a lithic damage to the ribs. In addition, during the radiography of the chest, there was an involvement in the process of neighboring structures. In 5 cases, the pathological process was distributed to the spine.
- With an MRI study, in 3 cases, the degree of intraositive distribution was demonstrated and in 2 cases, the involvement of the bone marrow was excluded in the formation of echinococcal cyst.
- Serological analysis was positive in 6 cases.
- The volume of operations carried out patients - resection of affected ribs. In addition, in 5 cases, the scraping of the affected vertebra is made, in 4 cases resection of the transverse process of the vertebra.
- Histological studies of macro production in all cases confirmed the diagnosis of echinococcosis.
- In 11 cases, patients were conservative therapy with albandazole drug.
- On average, all patients were examined for 2 years. Treatment forecast in all cases is indicated as favorable.

Conclusions

In medical practice, echinococcal cysts can affect all chest departments, including an isolated lesion of the ribs. Echinococcosis of ribs is a very rare disease, however, the cases described by the authors demonstrate the significance of this disease for the differential diagnosis.

As in the case of the described clinical cases analyzed by us, the echinococcosis process of the ribs is a random surgical find. Differential diagnosis is difficult due to anamnesis of the disease. A thorough study of chest radiographs with additional computed tomography helps determine the presence of this pathology. According to the results of our study, the X-ray picture may be atypical, and interpretation is difficult.

According to the analysis of the analysis, the treatment of patients included full resection of affected edges, up to the scraping of the affected vertebra, with resection of the

transverse process. In our case, an operation was carried out - under the supervisory resection of the affected edge in combination with drug therapy, which also gave a positive result of treatment.

References

1. Abdybekova A, Sultanov A, Karatayev B, Zhumabayeva A, Shapiyeva Z, Yeshmuratov T, Toksanbayev D, Shalkeev R, Torgerson PR. Epidemiology of echinococcosis in Kazakhstan: an update. *J Helminthol.* 2015 Nov;89(6):647-50. doi: 10.1017/S0022149X15000425. Epub 2015 Jul 10. PMID: 26160276. URL:<https://pubmed.ncbi.nlm.nih.gov/26160276/>
2. El Oueriachi F, Traibi A, El Hammoumi M, Arsalane A, Kabiri el H. *Updates Surg.* 2012 Mar; 64(1):49-52. Costal hydatidosis: management and outcome of five cases. URL:<https://pubmed.ncbi.nlm.nih.gov/22161278/>
3. Levy Faber D, Best LA, Militianu D, Ben Nun A. Thoracic outlet syndrome caused by hydatid cyst of the first rib-rare but important. *Indian J Surg.* 2010 Dec; 72(6):485-7. URL: <https://pubmed.ncbi.nlm.nih.gov/22131660/>
- 4 - WHO / OIE, 2019 FAO, OIE, and WHO launch a guide for countries on taking a One Health approach to addressing zoonotic diseases. Rome/Paris/Geneva, 11 March 2019 URL:<https://www.oie.int/en/for-the-media/press-releases/detail/article/fao-oie-and-who-launch-a-guide-for-countries-on-taking-a-one-health-approach-to-addressing-zoonoti/>
- 5 –Zhanna Shapieva Candidate of Biological Sciences, Report of the Chief Specialist Department for the Prevention of Parasitic Diseases of the Branch of SanEpidExpertiza NPC and Monitoring, Almaty November 2020.
- 6 - A. Chafik, 1,* A. Benjelloun, 2 A. El Khadir, 1 R. El Barni, 1 A. Achour, 1 and M. A. Ait Benasser Hydatid Cyst of the Rib: A New Case and Review of the Literature Copyright © 2009 A. Chafik et al. <https://www.ncbi.nlm.nih.gov/pmc/articles/PMC2825664/>
- 7 - Karaoglanoglu N, Gorguner M, Eroglu A. Hydatid disease of the rib. *Ann Thorac Surg* 2001; 71:372–3 URL:<https://www.ncbi.nlm.nih.gov/pmc/articles/PMC1808269/>
- 8 - Aghajanzadeh M, KhajehJahromi S, Hassanzadeh R, et al. Posterior mediastinal cyst. Posterior mediastinal cyst. *Arch Iran Med.* 2014;17(1):95– 96. URL: <https://pubmed.ncbi.nlm.nih.gov/24444071/>
- 9 - Stamatis, D Greschuchna. Echinococcus cysticus costalis: report of 2 cases and review of the literature Germany 1989 Apr;43(4):213-6. G URL:<https://pubmed.ncbi.nlm.nih.gov/2660129/>

- 10 - Stoss S, Kalbermatten DF, Robertson A, et al. Large cystic tumour at the chest wall mimicking an echinococcosis: a case report. *Journal of Plastic, Reconstructive and Aesthetic Surgery*. 2008;61(10):e13–e16.
- 11 - Tomos P, Kakaris S, Lachanas E, Karakatsani A. Secondary echinococcosis of the rib and soft tissues. *Respiration*. 2005;72(5): P. 542.
- 12 - Gezer S, Altinok T, Agaçkır Y, Tastepe I. Hydatid disease of the first rib causing thoracic outlet syndrome. *Medical Principles and Practice*. 2007;16(1):68–70.
- 13 - Findikcioglu A, Kilic D, Hatipoglu A. Primary hydatid disease of the chest wall. *Annals of Thoracic and Cardiovascular Surgery*. 2007;13(3):203–205.
- 14 - Ospanova K.B., Lapshina L.N., Brick T.M., Shayzadina F.M., Alyusheva N.O., Lavrinenko A.I., Asenova L.h. *Epidemiological research methods. Epiddiagnosis: Methodological manual*. - Karaganda, 2003. - 80 P.
- 15 - *Surgery Echinococcus* Yu.L. Shevchenko, F.G. Names 2016. Moscow 289 P.