

Prospects of artificial intelligence in carrying out the oncological component of the medical examination of the population

Cherenkov Vicheslav Grigorevich

*Doctor of Medical Sciences, Full Professor
Institute of Medical Education
Yaroslav-the-Wise Novgorod State University*

Veber Viktor Robertovich

*Doctor of Medical Sciences, academician RAN, Head of the Department
Yaroslav-the-Wise Novgorod State University*

Pasevich Konstantin Grigorevich

*Candidate of Medical Sciences, Head of the oncological dispensary
Yaroslav-the-Wise Novgorod State University*

Annotation. Creation of a robotic complex (RC) with a program for interviewing with illustrations (by the type of whether there are similar forms of pathology) of major tumors, a portable USB microscope built into a flexible hose and the body of the complex for transmitting pathological changes of visible localizations to the touch screen. To detect the activation of early signs of pigmented nevi and superficially spreading melanomas, they were stained with picofuxin (Patent for invention No. 2716811 of March 16, 2020). The survey was conducted in 1638 patients with a trajectory for men and women on a touch screen. The use of RC allowed us to suspect the activation of pigmented nevi, tumors of the skin, oral cavity, thyroid gland, and enlarged lymph nodes in $9.03\% \pm 1.3$ patients, of which $31.08\% \pm 1.8$ were able to confirm oncopathology on further examination. In the presence of complaints from the stomach on an empty stomach, 107 patients underwent a "breath test" on a Helik®-Scan, built into the RC program. The color change in the "breathing tubes" was scanned with fixation on the touch screen, in 29 of them, Helicobacteriosis was detected above 10 units. with a load. 17 patients were diagnosed with grade 1 and 2 metaplasia, 4 with gastric ulcer, and 3 of them with malignancy. In 20 patients, type 2 diabetes mellitus was detected for the first time as a risk factor for the development of tumor diseases by a non-invasive method. The results of the examination by the program of the complex with recommendations were sent via an On-line connection to the general practitioner.

Keywords: *robotic complex, survey with illustrations, "breath test", USB microscope, picofuxin, diabetes mellitus*

And although malignant tumors are extremely diverse and difficult to diagnose, a lot is known about the risk factors and mechanisms of cancer development, so that now in most cases, not only timely diagnosis and treatment, but also taking an active position in assessing the specific risk, successfully conduct prevention. The doctor should conduct a systematic examination of the patient not when something "hurts", but regularly, when nothing hurts, taking into account the risk groups, gender and age when contacting the doctor for any reason.


Early forms of cancer are preceded by a long period of carriage of oncogenic viruses, Helicobacter pylori and dysplasia, which can be established and cured. With a large flow of information during mass screening, asymptomatic signs of an early focus of developing cancer in organs and systems, the doctor's time limit, often limited to one question "What is Bothering

you?". Naturally, asymptomatic pathological processes with this approach, against the background of concomitant diseases, go into the background. And this is the weakest link in primary diagnostics, which requires the creation and implementation of digital technologies that increase "oncological alertness" at the primary stage [1,2].

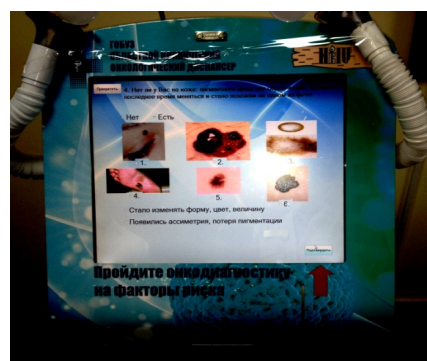The goal is to find solutions to the problems of increasing the effectiveness of detecting oncological pathology and risk factors by using a robotic complex for a system survey-examination of the main localizations to reduce the time spent by the doctor prior to his appointment.

Material and methods

Robotic intelligence is a method that allows you to implement algorithms for multi-purpose and system analysis in the diagnosis. The study of the effectiveness of the robotic complex was carried out on the basis of the created system examination program with illustrations, a touch screen, magnifying diagnostics (including a portable USB microscope with an LED) of visual localities (skin, oral cavity), non-invasive determination of sugar, "respiratory urease test". Then an assessment was carried out, recommendations for further tactics were formed, and the results were transmitted to the doctor. Previously, a large-format digital television screen is installed in the waiting hall of the polyclinic, which is associated with the prevention program and explains the tasks of the need to pass the robotic complex (like a slide show). The survey program of the robotic complex is carried out on the touch screen. At the beginning, the passport data is filled in Fig. 1 (a).



a)



b)

Fig 1. Touch screen: a) keyboard for filling in passport data; b) Questions with illustrations of pigmented tumors.

Then follow the questions on the main localizations with illustrations of (melanoma and non-melanoma) tumors (Fig. 2b), precancerous skin conditions, risk factors and other conditions, organ systems, lifestyle and habits

For example:

1. Do you have any skin problems (sores, cracks, or others?) formations that have recently:
 1. Yes, it is possible to change the shape, color or size
 2. Yes, there was a tumor spreading over the skin, in places with raised edges other changes, sometimes itching
 3. Yes, there is an ulcer on the skin that does not heal for more than 3-4 weeks*
 4. Yes, there is a formation in the form of a skin-colored plaque with a depression in the center, raised shiny pearlescent edges
 5. Yes, there are, but I do not know how to evaluate

6-Yes, there are several signs

7. No, nothing

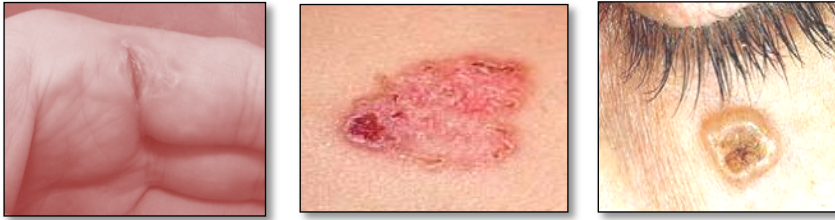

Fig.2. Precancerous changes and basal cell forms of cancer.

2. Do you have a pigmented spot(s) in the area of the face,back, neck, including the nail bed (without bruising) or other places, including under magnification ?

Yes No

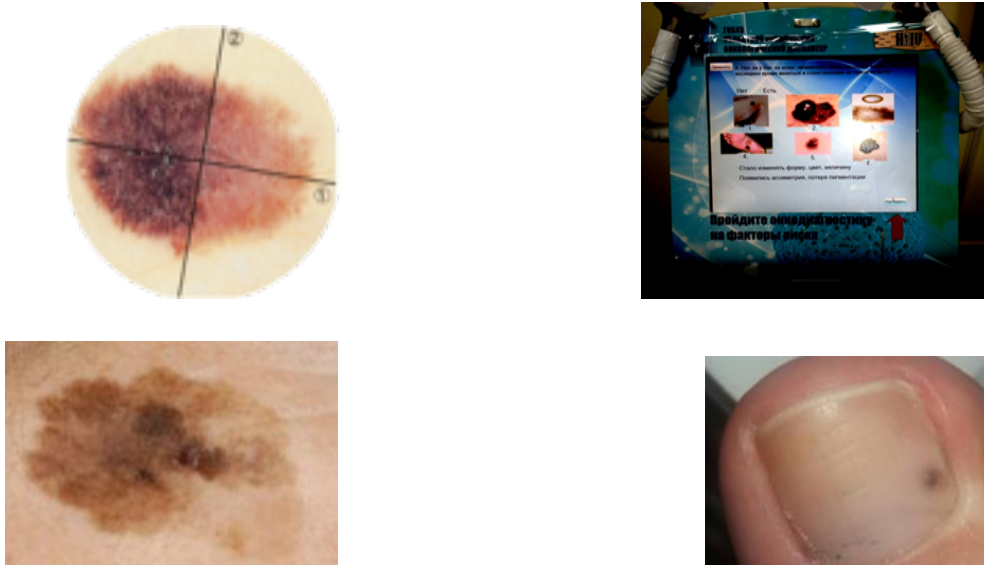


Fig.3. Do you have a pigmented spot(s) in the area of the face, back, neck, including the nail bed or other places, including under magnification?

Given the extremely high rate of advanced cases of oral cancer, we integrated a portable USB microscope with an LED into a flexible hose that enters the side of the body of the robotic complex to transmit pathological changes in the skin and oral cavity to the touch screen. Suspicious areas can be zoomed in or out on the screen to detect signs of malignancy.



Fig. 4. Examination of the oral cavity (under the tongue).

On the front panel of the case, a ring is fixed for a container with disposable spatulas in sterile bags in order to displace the mucous membrane of the cheek and tongue for examining the hidden places of the oral cavity.

For the accuracy of the assessment of pigmented nevi, the magnifying magnifier and mirror were replaced with a USB portable digital microscope with pre-staining with picrofuxin for 7-10

minutes [3,4]. After absorption through the epithelium, allows detecting violations of the rhomboid shape of collagen fibers, the appearance of pigment globules, etc. identify the first signs of the transformation of the pigmented nevus into melanoma on the computer screen (Fig. 5).

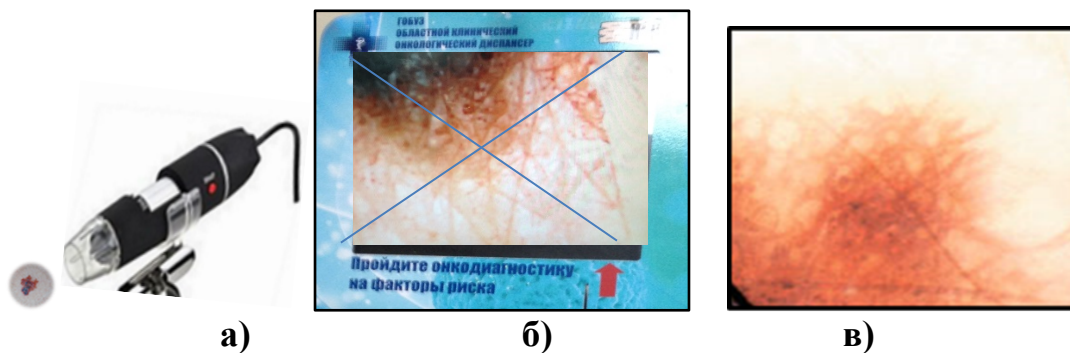


Fig. 5. Pigmented formations under a microscope with picrofuxin staining: a) USB microscope x 100; б) Fibers diamond-shaped depart from a simple nevus; в) collagen fibers depart chaotically with point inclusions.

The survey organizer is a specially trained nurse operator or midwife of the examination room. which includes a robotic system and code registration. The nurse operator helps to answer questions, signs or factors that cause difficulties for the patient. The survey trajectory is based on gender and clarifying factors .

As you know, stomach cancer occupies a leading place among other malignant tumors. The proven cause of stomach diseases is the bacterium *Helicobacter pylori*. In the presence of the slightest complaints from the stomach and other digestive organs, it is recommended to conduct a sensitive "breath test" based on the "Helik®-Scan" (AMA company), built on the front panel of the robotic complex.

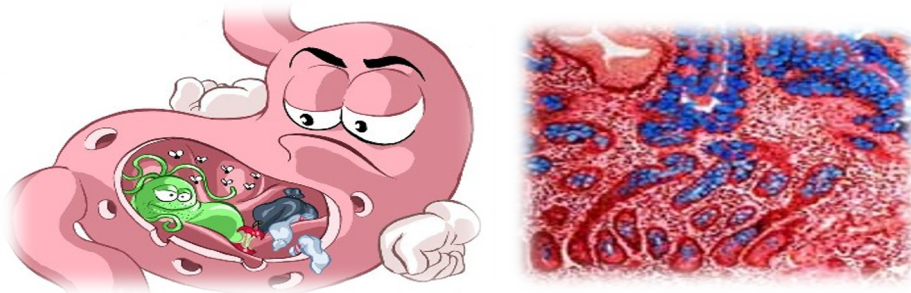


Fig.6. Stomach with Helicobacteriosis.

Two "breath tests" were performed on an empty stomach : before taking urea (basal test) and after (with exercise). In case of infection with *Helicobacter pylori*, a second test (with a load of urea or urea) on the screen, the blue bar in comparison with the basal test significantly increased in proportion to the percentage of ammonia in the exhaled air. The program in the "on line" mode reflected the change the length of the second sample on the screen, respectively, is the infection of the stomach with *Helicobacter pylori*.

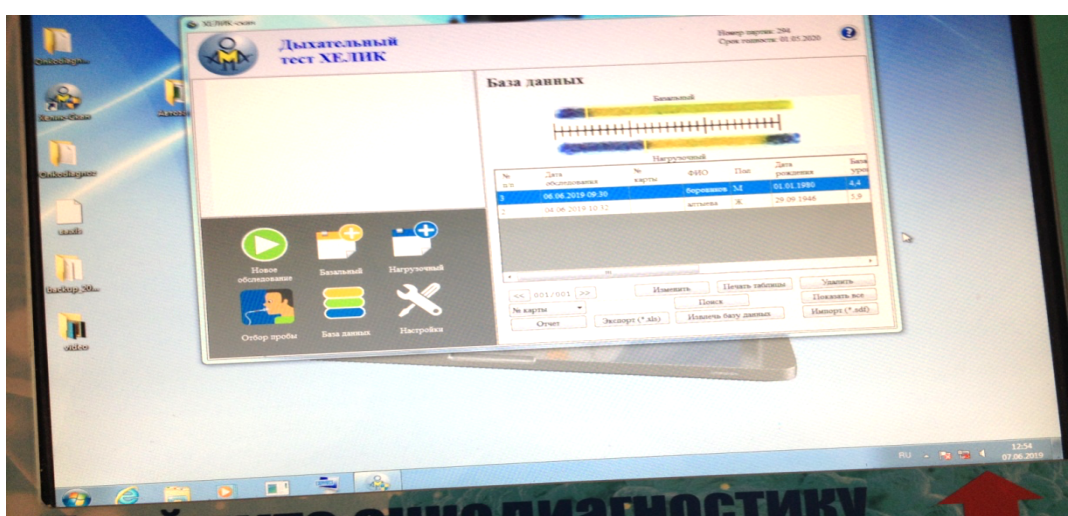


Fig.7. Results of patient P., 42 years old.

In Figure 7 - On the right in the upper rectangle, two yellow stripes are visible (the upper one - one end turned blue after basal respiration -4.9 units; the lower one - after exercise -10.8 units).

Results. The studies were conducted in 1,657 patients who applied to the regional clinical oncology dispensary on the "Open Day" and after advertising exhibitions. The use of the robotic complex is suspected: tumors of the skin, oral cavity, thyroid gland, enlarged lymph nodes in (168 patients) $10.01\% \pm 1.3$, of which (46 patients) $31.08\% \pm 1.8$ with further examination, oncopathology was confirmed, including 3 patients with melanoma, 5 with basal cell carcinoma and in one case with thyroid cancer and in two with oral cancer. In addition, 8 patients were found to have melanoma-like nevi.

Table 1. Survey results with illustrations and chromo microscopy

Installed

Localization	Number of patients with suspected pathology	Precancerous changes, risk, milano-dangerous nevi	Malignant diseases tumors
Skin	16	8	8
Oral cavity	11	9	2
Lymph Nodes	19	19	-
Shields. iron	44	43	1
Moloch. iron	58	56	2
Diabetes mell.	20	20	
Total	168	155 (9,3%)	13 (0,7)

58 patients with complaints of certain phenomena of stomach discomfort were given a "breath test" for 6 minutes the next day, 29 of them had helicobacteriosis above 10 units. with a load. All these patients underwent fibrogastroscopy (FGS) with biopsy for atypical cells and Helicobacter pylori for reliability. 17 patients had metaplasia of the 1st or 2nd degree, 4 had gastric ulcer and 3 of them had malignancy. In 20 patients type 2 diabetes mellitus was detected for the first time as a risk factor for tumor diseases by a non-invasive method .

All results of the RC program via the local Internet system and recommendations for further tactics should be sent to the attending physician, who, after the necessary additional examination of the patient, established the final diagnosis or referred to the necessary specialist.

Discussion

The RC and preliminary results described in this paper, taking into account the methods of targeted survey with illustrations used in the screening of persons who applied in terms of experimental examination, showed that the detection rate of malignant tumors was $0.7 \pm 1.2\%$, precancerous changes and melanoma-threatening pigmented nevi $0,48.2 \pm 2.2\%$. For the accuracy of the assessment of pigmented nevi, the magnifying glass was replaced with a USB portable digital microscope with pre-staining with picrofuxin. Moreover, the melanoma can not be injured and perform a biopsy.

The use of a Helik®- scan in a complex digital program allows you to determine the causes of gastric discomfort. When the level of Helicobacter pylori infection exceeds 10 units, eradication and fibrogastroscopy are required, in which the detectability of grade 1-2 metaplasia and peptic ulcer disease was 7 пациентов, including malignancy in 3 cases.

Conclusions:

1. Conducting explanatory preventive work on digital television screens like a "slide show" in the halls of polyclinics increases the cancer literacy of patients, the purposefulness of passing their dispensary examination and the need for screening.

2. The results of the introduction of the robotic complex at the pre-medical stage allows you to save the time of a general practitioner for a systematic examination and identification of cancer risk factors and early forms of cancer ($0.79\% \pm 1.2$), precancerous changes and melanoma-prone pigmented nevi- $0,48.2 \pm 2.2\%$, the treatment of which is less expensive.

3. Digital technologies in the examination of patients are a real breakthrough in the primary diagnosis of risk factors and early forms of cancer, requiring their adaptation for each polyclinic and paramedic-obstetric stations with some improvement in the program and organization of the production of robotic complexes.

References

1. Cherenkov V. G., Makarov V. A., Kostyukov A. Ways of creating artificial Intellect in education and carrying out cancer component of medical examination (screening) of the population// MOJ Tumor Research, Washington. August 07, 2018, p. 136-138.
2. Cherenkov V. G., Pasevich K. G., Gudkov I. V. Robotic intelligence in the organization of pre-medical diagnostics of the risk of tumor diseases// Russian Journal of Oncology, vol. 25, no. 2, 2020, P.72-75.
3. Cherenkov V. G., Pasevich K. G. art. Riss M. E., Naumenko E. S. Method for diagnosing surface-spreading melanomas// Patent for invention No. 2716811 dated March 16, 2020. VNIIGPE.
4. Diagnostics of Early Signs of Surface-Spreading Melanoma Using A Robotic Complex//Journal of Clinical Trials & Research JCTR, 2020, 3(1): 174-179. Cherenkov V. G. Pacewicz K. G, Riss M.E, Naumenko E.S.